

Long-Term Effects of Botulinum Toxin Type A (Botox) on Facial Lines

A Comparison in Identical Twins

William J. Binder, MD

Objective: To evaluate the presence of imprinted facial lines in identical twin sisters, one of whom had received botulinum toxin type A (Botox) treatment in the forehead and glabellar region regularly for 13 years and one of whom had not. Crow's feet were also compared.

Methods: One twin received Botox in the forehead and glabellar region (approximately 2 to 3 times each year over the past 13 years) and in the crow's feet (twice in past 2 years). Her twin received Botox only twice (in the forehead and glabellar region, 3 and 7 years ago).

Results: Imprinted forehead and glabellar lines were not evident in the regularly treated twin but were evident in

the minimally treated twin. Crow's feet were less noticeable when the regularly treated twin smiled (even at 7 months after treatment) than when the minimally treated twin smiled. Untreated facial areas (eg, nasolabial folds) showed comparable aging in both twins. Neither twin experienced adverse effects.

Conclusions: Long-term treatment with Botox can prevent the development of imprinted facial lines that are visible at rest. Botox treatment can also reduce crow's feet. Treatment is well tolerated, with no adverse events reported during 13 years of regular treatment in this study.

Arch Facial Plast Surg. 2006;8:426-431

HYPERFUNCTIONAL LINES such as horizontal forehead lines, glabellar lines, and crow's feet can develop from the repeated contractions of certain muscles (the frontalis, procerus, corrugator, and orbicularis oculi muscles). By blocking the release of acetylcholine from the presynaptic terminal of the neuromuscular junction, botulinum toxin type A (Botox; Allergan Inc, Irvine, Calif) can inhibit the contraction of these muscles.

Botox is approved by the US Food and Drug Administration for the treatment of glabellar lines, and its efficacy in the treatment of these and other hyperfunctional facial rhytides (eg, horizontal forehead lines and crow's feet) is well documented.¹⁻¹⁰ Its duration of effect when used for the treatment of glabellar lines is generally at least 3 to 6 months and has been reported to be effective up to 11 months.^{6,11} Furthermore, it appears that repeated treatments can result in a progressively longer duration of action.⁵ (Note: Dosing and results reported in this study are specific to the formulation of Botox manufactured by Allergan Inc. The Allergan Inc formula-

tion is not interchangeable with other botulinum toxin products and cannot be converted by using a dose ratio.)

Most published studies evaluate the efficacy and tolerability of Botox for no more than 1 year, and there are few reports evaluating the clinical benefits of repeated treatments over the course of many years. Nevertheless, patient satisfaction is generally high, and it is likely that many patients will continue treatment for several years.^{2,12-15} Although controlled studies of this duration are impractical, the evaluation of facial lines in identical twins who have had different exposures to Botox can offer insight into the long-term benefits of Botox treatment. This report evaluates the presence of hyperfunctional facial lines in identical twin sisters, one of whom had regular Botox treatment in the forehead and glabellar regions over many years and one of whom did not.

METHODS

Hyperfunctional facial lines were evaluated in identical 38-year-old twin sisters. The first twin (hereafter, the regularly treated twin) had received Botox injec-

Author Affiliation: Department of Head and Neck Surgery, UCLA School of Medicine, Los Angeles, Calif.

Table. Botulinum Toxin Type A (Botox)* Treatments Administered

Area of Injection	Injection Sites	Injection Volume, mL	Dose per Injection	Total Dose per Treatment Session, U	Duration of Continued Treatment in Regularly Treated Twin, y
Forehead lines	8-12 Sites in the frontalis muscle, spaced at 2- to 2.5-cm intervals	0.1	2.5 U	20-30	13
Glabellar lines	1 In procerus and 2 per side in medial and midlateral corrugator	0.1-0.2	2.5-5 U (dilution was 2 mL/100 U in years 0-3 and 4 mL/100 U in years 4-13)	15-25	13
Crow's feet	4-6 In each orbicularis oculi, including the lateral and superior infrabrow area; injections placed as far laterally as the crow's feet were visible	0.1-0.15	2.5-3.75 U	15-20 per facial side	2

*Allergan Inc, Irvine, Calif.

tions in the forehead region and the glabellar region approximately 2 to 3 times each year over the past 13 years (**Table** and **Figure 1**). She had also received a total of 2 treatments with Botox in the crow's feet area in the last 2 years (Table and Figure 1). She was last treated with Botox more than 4 months before the "at rest" photographs of the forehead, glabellar, and crow's feet were taken and 7 months before the "when smiling" photographs of the crow's feet were taken. The other twin (hereafter, the minimally treated twin) received only 2 treatments with Botox, both in the forehead and glabellar regions. The first of these was administered 7 years ago, and the second was administered 3 years ago.

RESULTS

In this study, neither twin experienced any adverse effects from Botox.

FOREHEAD AND GLABELLAR LINES

Photographic documentation shows that hyperfunctional forehead and glabellar lines are not evident at rest in the regularly treated twin. In contrast, they are visible in the minimally treated twin (**Figure 2** and **Figure 3**).

CROW'S FEET

At rest, there were no marked differences between the twins in terms of crow's feet (Figure 3). This is not unexpected because the regularly treated twin had started receiving Botox injections in the crow's feet area only 2 years previously.

When the twins smiled, there was a marked difference between their crow's feet (**Figure 4**).

NASOLABIAL FOLDS

Neither twin received any Botox injections in the lower half of the face, and the nasolabial folds in the regularly

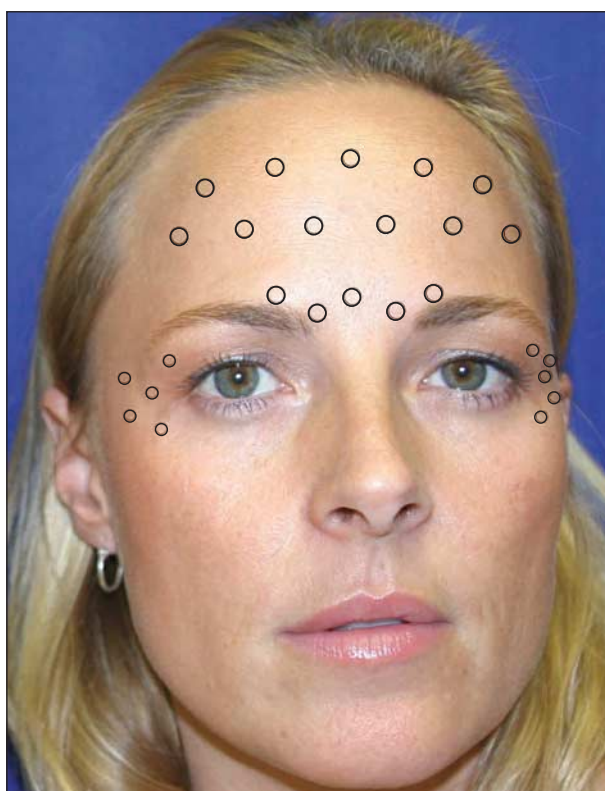


Figure 1. Approximate sites of botulinum toxin type A (Botox; Allergan Inc, Irvine, Calif) injections in the forehead, glabellar, and crow's feet regions.

treated twin were at least as noticeable at rest as those in the minimally treated twin (Figure 3). This suggests a generally similar degree of aging in untreated areas of the face in both twins, giving credence to the belief that the differences between the twins in the severity of their forehead and glabellar lines are attributable to the difference in the number of Botox treatments that each received over a long period of time (rather than a greater propensity for skin aging in the minimally treated twin).

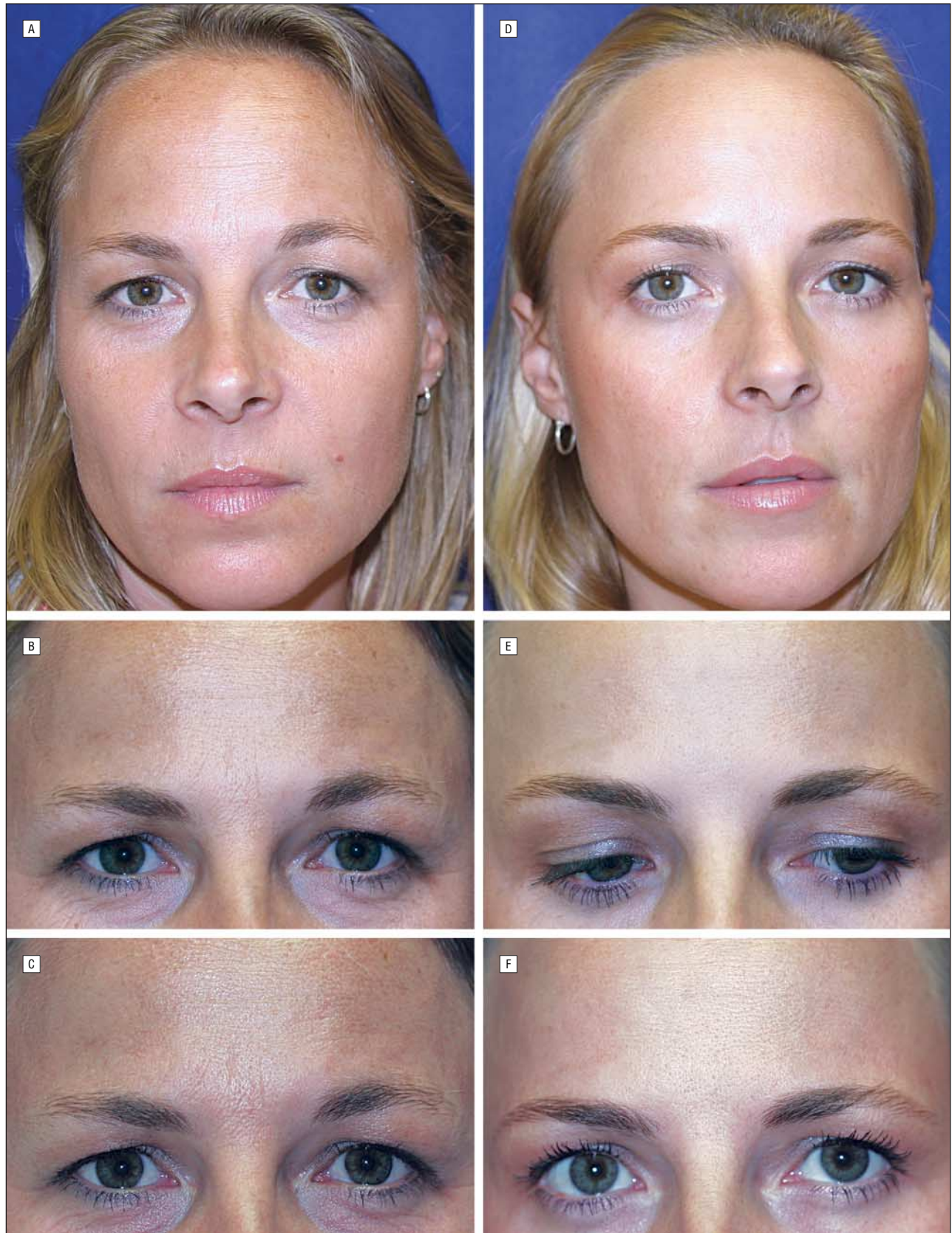

Figure 2. The minimally treated twin (A, B, and C) and the regularly treated twin (D, E, and F). Hyperfunctional lines in the forehead (B and E) and glabellar regions (C and F) are visible in the minimally treated twin but not in the regularly treated twin.

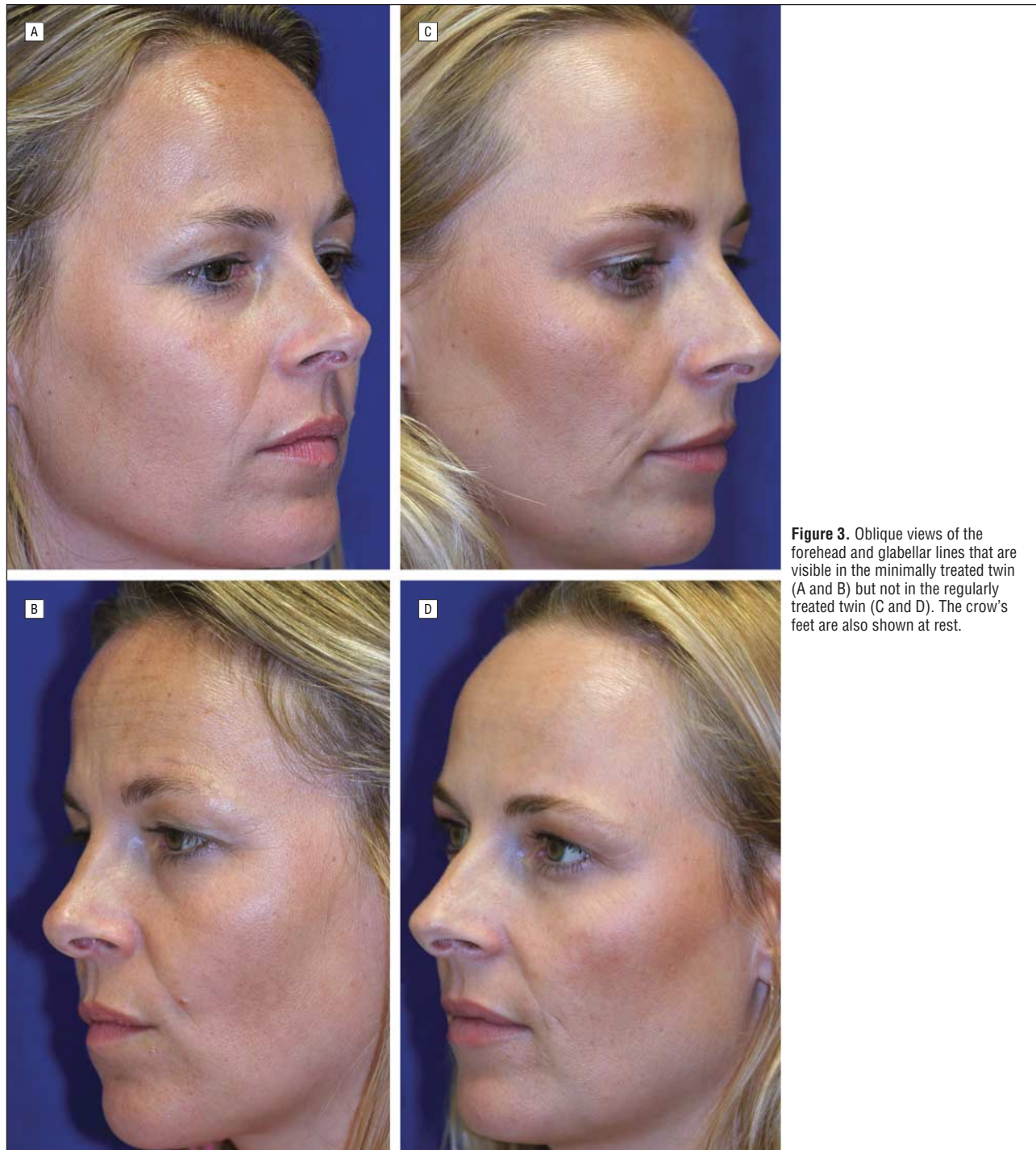

Figure 3. Oblique views of the forehead and glabellar lines that are visible in the minimally treated twin (A and B) but not in the regularly treated twin (C and D). The crow's feet are also shown at rest.

COMMENT

It is well known that a single injection of Botox into a target muscle can inhibit a patient's ability to contract that muscle for several months and so reduce the appearance of facial lines that would have been apparent during active muscle contraction. The results presented herein suggest that long-term treatment can also result in additional benefits and prevent the formation of *permanent* lines—so-called imprinted lines—that slowly manifest over time as part of nor-

mal aging as a result of dermal and epidermal tissue breakdown caused by repeated muscle contractions. This comparison of identical twins (one of whom received regular injections of Botox in the forehead and glabellar region for 13 years and one of whom did not) demonstrates that long-term treatment with Botox can prevent the development of these imprinted facial lines.

Once these lines develop, they can be rectified only by using other treatment modalities such as fillers or skin resurfacing techniques. As long-term Botox treat-

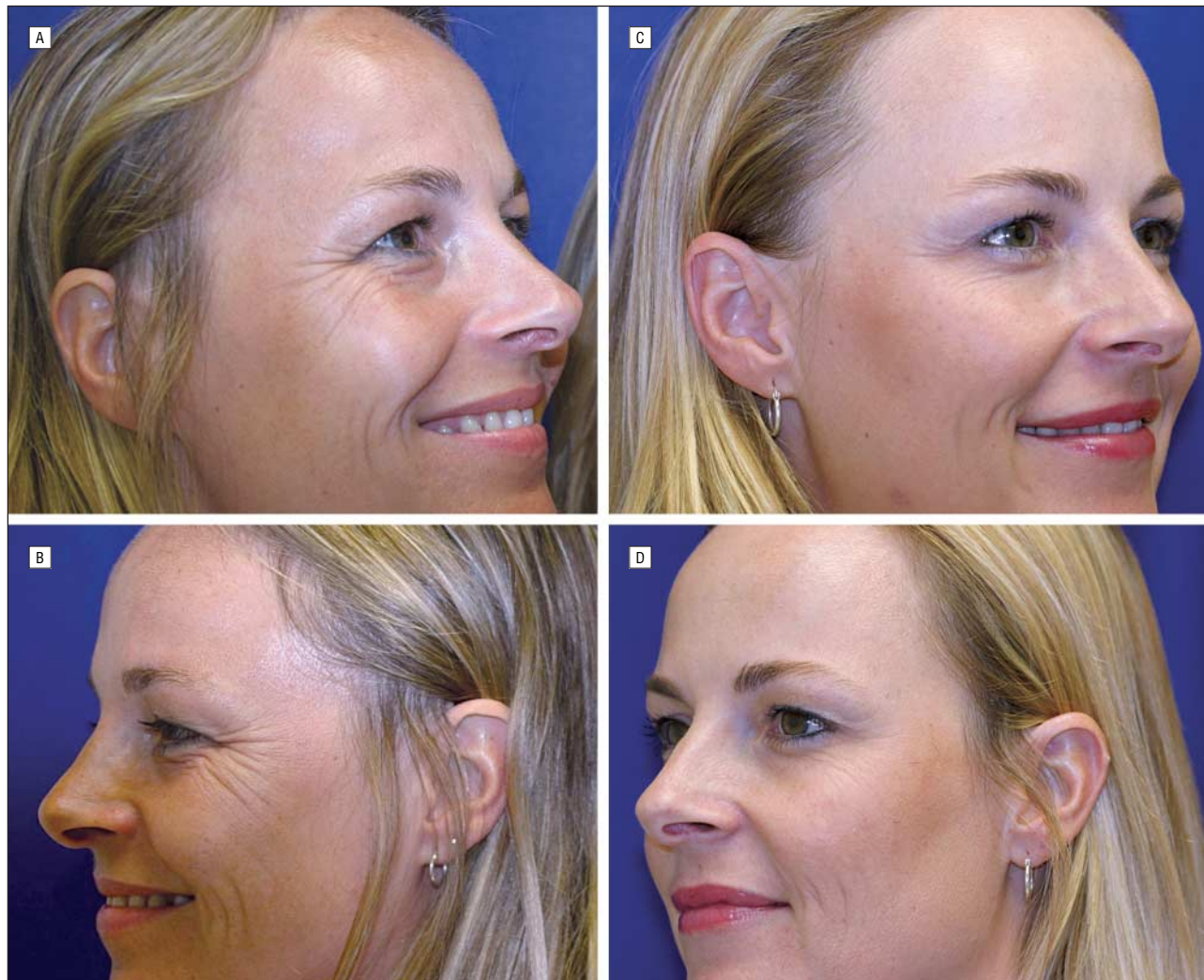

Figure 4. Crow's feet when smiling are more visible in the minimally treated twin (A and B) than in the regularly treated twin (C and D), even though the crow's feet of the regularly treated twin had been treated with botulinum toxin type A (Botox; Allergan Inc, Irvine, Calif) only twice in the last 2 years.

ment appears able to dramatically slow, if not halt, this aspect of the aging process, it would also appear able to delay, if not avoid, the need for such treatment.

It is likely that long-term treatment with Botox is able to prevent the development of imprinted lines not only by inhibiting the patient's ability to contract the target muscle but also perhaps through behavioral modification. With long-term treatment, the patient may become used to having little, if any, need or ability to contract the target muscle and may eventually "learn" to avoid even trying to contract it. It is also thought that, by relieving the mechanical pressure of chronic muscle contraction in this way, dermal remodeling may be facilitated.⁶

In the regularly treated twin, the clinical effect of Botox was consistently sustained for at least 6 months after each injection, and the duration of effect did not diminish with repeated treatments. The dosage also remained stable over the 13 years of treatment. It has been reported in the literature that, compared with a single treatment, repeated injections may enhance response rates, prolong the duration of action, and lower the incidence of adverse events.^{5,10} If greater or more prolonged effi-

cacy is achieved with continued treatment, this may afford the opportunity to treat patients less frequently or with lower doses.

In conclusion, long-term treatment with Botox can prevent the development of imprinted facial lines that are visible at rest. Botox treatment can also reduce the appearance of crow's feet. Treatment is well tolerated, with no adverse events reported during 13 years of regular treatment in this study.

Accepted for Publication: June 1, 2006.

Correspondence: William J. Binder, MD, 120 S Spalding Dr, Suite 340, Beverly Hills, CA 90212-1800 (info@doctorbinder.com).

Financial Disclosure: Dr Binder is a stockholder of and a consultant to Allergan Inc.

Previous Presentations: This study was presented in part at the Rejuvenation of the Aging Face Course—2006, sponsored by the American Academy of Facial Plastic and Reconstructive Surgery; February 19-23, 2006; Boca Raton, Fla; and as a poster at the 64th Annual Meeting of the American Academy of the Dermatology; March 3-7, 2006; San Francisco, Calif.

Acknowledgment: I am grateful to Gill Shears, PhD, for assistance with the writing of this article.

REFERENCES

1. Carruthers J, Fagien S, Matarasso SL; Botox Consensus Group. Consensus recommendations on the use of botulinum toxin type A in facial aesthetics. *Plast Reconstr Surg.* 2004;114(6)(suppl):1S-22S.
2. Carruthers A, Carruthers J, Said S. Dose-ranging study of botulinum toxin type A in the treatment of glabellar rhytids in females. *Dermatol Surg.* 2005;31:414-422.
3. Carruthers A, Carruthers J. Prospective, double-blind, randomized, parallel-group, dose-ranging study of botulinum toxin type A in men with glabellar rhytids. *Dermatol Surg.* 2005;31:1297-1303.
4. Carruthers A, Carruthers J, Cohen J. A prospective, double-blind, randomized, parallel-group, dose-ranging study of botulinum toxin type A in female subjects with horizontal forehead rhytides. *Dermatol Surg.* 2003;29:461-467.
5. Carruthers JA, Lowe NJ, Menter MA, et al. A multicenter, double-blind, randomized, placebo-controlled study of the efficacy and safety of botulinum toxin type A in the treatment of glabellar lines. *J Am Acad Dermatol.* 2002;46:840-849.
6. Carruthers JD, Lowe NJ, Menter MA, Gibson J, Eadie N; Botox Glabellar Lines II Study Group. Double-blind, placebo-controlled study of the safety and efficacy of botulinum toxin type A for patients with glabellar lines. *Plast Reconstr Surg.* 2003;112:1089-1098.
7. Lowe NJ, Ascher B, Heckmann M, et al. Double-blind, randomized, placebo-controlled, dose-response study of the safety and efficacy of botulinum toxin type A in subjects with crow's feet. *Dermatol Surg.* 2005;31:257-262.
8. Lowe NJ, Lask G, Yamauchi P, Moore D. Bilateral, double-blind, randomized comparison of 3 doses of botulinum toxin type A and placebo in patients with crow's feet. *J Am Acad Dermatol.* 2002;47:834-840.
9. Keen M, Blitzer A, Aviv J, et al. Botulinum toxin A for hyperkinetic facial lines: results of a double-blind, placebo-controlled study. *Plast Reconstr Surg.* 1994;94:94-99.
10. Carruthers A, Carruthers J, Lowe NJ, et al. One-year, randomised, multicenter, two-period study of the safety and efficacy of repeated treatments with botulinum toxin type A in patients with glabellar lines. *J Clin Res.* 2004;7:1-20.
11. Carruthers JD, Carruthers JA. Treatment of glabellar frown lines with C. botulinum-A exotoxin. *J Dermatol Surg Oncol.* 1992;18:17-21.
12. Sommer B, Zschocke I, Bergfeld D, et al. Satisfaction of patients after treatment with botulinum toxin for dynamic facial lines. *Dermatol Surg.* 2003;29:456-460.
13. Foster JA, Barnhorst D, Papay F, Oh PM, Wulc AE. The use of botulinum A toxin to ameliorate facial kinetic frown lines. *Ophthalmology.* 1996;103:618-622.
14. Kowalski J, Ravelo A, Saulay M, et al. Patient self-perceptions and satisfaction with botulinum toxin type A treatment for moderate to severe crow's feet: results from a placebo-controlled clinical study. Poster presented at the Annual Meeting of the American Academy of Dermatology; July 20-24, 2005; Chicago, Ill.
15. Stotland MA, Kowalski JW, Ray BR. Patient-reported benefit and satisfaction with botulinum A toxin type A treatment of moderate to severe glabellar rhytids: results from a prospective open-label study. *Plast Reconstr Surg.* In press.

Announcement

Visit www.archfacial.com. As an individual subscriber you may view articles by a Topic Collection. Topic Collections group articles by topic area within a journal and across *JAMA & Archives Journals*. The Topic Collection displayed on each journal site shows the topic areas most relevant that journal's readership. You may use the Topic Collections list in 3 ways:

1. From the Collections page, click on a topic to view all articles in that topic in 1 journal or all journals.
2. From an article page, click on the topic collections associated with that article to view other articles on that topic.
3. Sign up to receive an alert when new articles in *JAMA & Archives Journals* are published on the topics of your choice.